



ORIGINAL RESEARCH

The pedicled Antero lateral thigh flap for gender affirming surgery: what is different? First case series outcomes of a single center from Turkey

Ersan Arda¹, Mehmet Gürkan Arıkan^{2,*}, Hüsametdin Top³

¹Department of Urology, School of Medicine, Trakya University, 22030 Edirne, Turkey

²Department of Urology, Hatay Dörtyol State Hospital, 31600 Hatay, Turkey

³Department of Plastic and Reconstructive Surgery, School of Medicine, Trakya University, 22030 Edirne, Turkey

***Correspondence**

mgarikan26@gmail.com

(Mehmet Gürkan Arıkan)

Abstract

The aim of this study is to share our preliminary outcomes of the pedicled Antero Lateral Thigh flap (ALTF) phalloplasty technique, which we presume to be the first reported case series of a single center from Turkey. A cross-sectional study, comprising all cases who underwent pedicled ALTF phalloplasty in our clinic, between January 2015 and December 2019, was designed. Demographic data, case characteristics and surgical details including complications were recorded. The mean age of our 26 cases was 30 (28–34) years. The mean penile length and diameter were 15.07 ± 0.98 cm and 3.9 ± 0.34 cm, respectively. Tactile sensation was evaluated by touching the radix, corpus and tip of the neo-phallus showing response in 17 (65.4%), 7 (26.9%) and 2 (7.7%) of the cases, respectively. In 14 (53.8%) of all our cases no complication was reported at all. However, in 12 (46.1%) cases, although no intraoperative complication occurred; postoperative complications were observed as Clavien-2 (3.8%), Clavien-3a (3.8%) and Clavien-3b (71%). Postoperative satisfaction rates were found 77.14% (38–94). Although relevant studies are limited, in addition to low complication rates and high satisfactory outcomes, by leading to a concealable donor site, the pedicled ALTF can be used as a preferred phalloplasty technique, especially in transmen with religious or cultural sensibility.

Keywords

Anterolateral thigh flap; Gender incongruence; Pedicled flap; Phalloplasty; Reconstruction; Transgender surgery

Colgajo anterolateral del muslo regional para cirugía genital transgénero. ¿Qué tiene de diferente? Primer reporte de serie de casos en un centro hospitalario de Turquía

Resumen

El objetivo de este estudio es compartir los problemas preliminares de la técnica de faloplastia pediculada con colgajo anterolateral de muslo (ALTF), que creemos que es la primera serie de casos de un solo centro en Turquía. Se diseñó un estudio transversal de todos los casos intervenidos de faloplastia con colgajo anterolateral del muslo regional (ALTF) de nuestro hospital entre Febrero de 2015 hasta Diciembre de 2019. Se registraron los datos demográficos, las características de los casos y los detalles quirúrgicos, incluyendo también las complicaciones. La edad media de nuestros 26 casos fue de 30 (28–34) años. La longitud y el diámetro medios del pene fueron de 15.07 ± 0.98 cm y 3.0 ± 0.34 cm, respectivamente. La sensación táctil se evaluó tocando la raíz, el cuerpo y la punta del neofalo mostrando respuesta en 17 (65.4%), 7 (26.9%) y 2 (7.7%) de los casos respectivamente. En 14 (53.8%) de todos nuestros casos no se reportó ninguna complicación. Sin embargo en 12 casos (46.1%) aunque no se presentó ninguna complicación transoperatoria; las complicaciones postoperatorias se presentaron Clavien-2 (3.8%), Clavien-3a (3.8%), Clavien 3b (71%). Se documentaron índices de satisfacción postoperatoria en el 77.14% (38–94). Además de la baja tasa de complicaciones y los resultados altamente satisfactorios, al ser un sitio anatómico oculto, el colgajo anterolateral del muslo regional (ALTF), se puede utilizar como técnica preferida de faloplastia, especialmente en hombres transgénero con presión religiosa o cultural.

Palabras Clave

Colgajo anterolateral del muslo regional; Incongruencia de género; Colgajo pediculado; Faloplastia; Reconstrucción; Cirugía transgénero

1. Introduction

Conflict between a person's gender identity and the assigned sex at birth, that leads to physical and emotional distress, is defined as Gender Incongruence (GI) [1]. It is reported that, to alleviate the stress caused by this condition and to facilitate gender role and change characteristics, surgical transition is one of the best available option [2]. The Standards of Care of the World Professional Association of Transgender Health (WPATH) has been composed to define diagnosis, follow-up and treatment options for transgender people [3].

Gender affirming surgery (GAS), commonly refers to all surgical procedures, involving facial, top and bottom surgery, that are performed to comprise the desired gender outlook of a person, in terms of cosmetic and functional purposes [2]. Tactile sensation, penetration ability, smooth micturition, minimal donor site morbidity and an aesthetic appearance are the most important goals described for a successful phalloplasty [4, 5]. However, optimal tissue supply for erectile, fascial and urethral structures, during neo-phallus reconstruction of trans men is not always easy to acquire [6].

Currently, considerable phalloplasty techniques, using different donor sites are published [7–10]. Among them, Antero Lateral Thigh flap (ALTh) which can be used free or pedicled is one of the main methods of choice, especially in our country, due to its invisible donor site, and low rejection rate [5, 7, 11].

The aim of this study is to share our preliminary outcomes, including complications and their management, of the pedicled ALTh phalloplasty technique applied to transgender individuals.

2. Material and methods

2.1 Study design and ethics details

A cross-sectional study, comprising all adult cases who underwent pedicled ALTh phalloplasty for female to male (FtM) GAS in our clinic, between January 2015 and December 2019, was designed. Examination of all cases prior to surgery was performed by both surgeons (urologist and plastic surgeon) simultaneously at the outpatient clinic. Demographic data including case characteristics, medical history and previous surgery details were recorded with the patient follow-up chart. In addition, intraoperative findings, early postoperative alterations and complications detected during follow-up examinations were classified and recorded to the same patient follow-up chart.

2.2 Inclusion and exclusion criteria

Our inclusion criteria for FtM GAS were (i) Gender Incongruence (GI) diagnosis by at least two psychiatrists; (ii) to be over 18 years of age; (iii) two years of real-life experiences in accordance with GI accompanied by psychotherapy; (iv) one year of hormone therapy; and (v) differential diagnosis of clinically identical disorders (psychotic disorder, physical intersex conditions, *etc.*). Patients who had undergone any surgical step or management of complications in another center were excluded.

2.3 Patient evaluation and outcomes

Depending on the technique that is used and the potential complications that can be observed, FtM GAS is commonly performed in two or three stages. In our routine practice, we prefer and offer a three staged surgical transition, in which early and late first follow-up examinations are done approx. 2 weeks and 3 months after discharge, at each surgical stage.

Assessment of complications that might occur after phalloplasty are made *via* clinical application and/or, for those who could not show up due to traveling issues, *via* telephone and/or electronic images. Most common complications are reviewed with a short checklist, but if necessary, opportunity has been given to explain them more detailed. In addition, cases who had to apply and were treated due to any complication elsewhere, were informed to provide feedback about their duration. Thus, no matter how minor or temporary, all complications are included in the study.

Since there is no defined standard evaluation protocol for the postoperative follow-up examination of transgender cases, a non-validated satisfaction inquiry consisting of 10 questions was adapted to evaluate general mental, social and physical conditions and to optimize our clinical process. In this inquiry, each question was designed with five choices of response resulting in a minimum of zero (definitely no) and a maximum of eight points (definitely yes) (Table 1). At the end of the inquiry, the total score between 0–80 points was calculated for each patient, which 80 points indicate 100% satisfaction rate and the mean value of all patients' scores, were designated as percentages, to evaluate satisfaction rates that included mental, physical and social health in general.

2.4 Surgical technique; description of pedicled ALTh phalloplasty

As mentioned before, FtM GAS is usually performed in a multi-staged fashion of which our surgical steps could be summarized as;

Stage 1: Creation of the neo-phallus by harvesting the ALTh, and midline repositioning at the level of the symphysis pubis;

Stage 2: (approx. 3–6 months later) Vaginal closure, urethral reconstruction (elongation of the urethra to the level of the clitoral hood or trans-positioning to the tip of the neo-phallus), glansplasty and/or scrotoplasty;

Stage 3: (approx. 6 months later) Implementation of penile and/or scrotal prostheses.

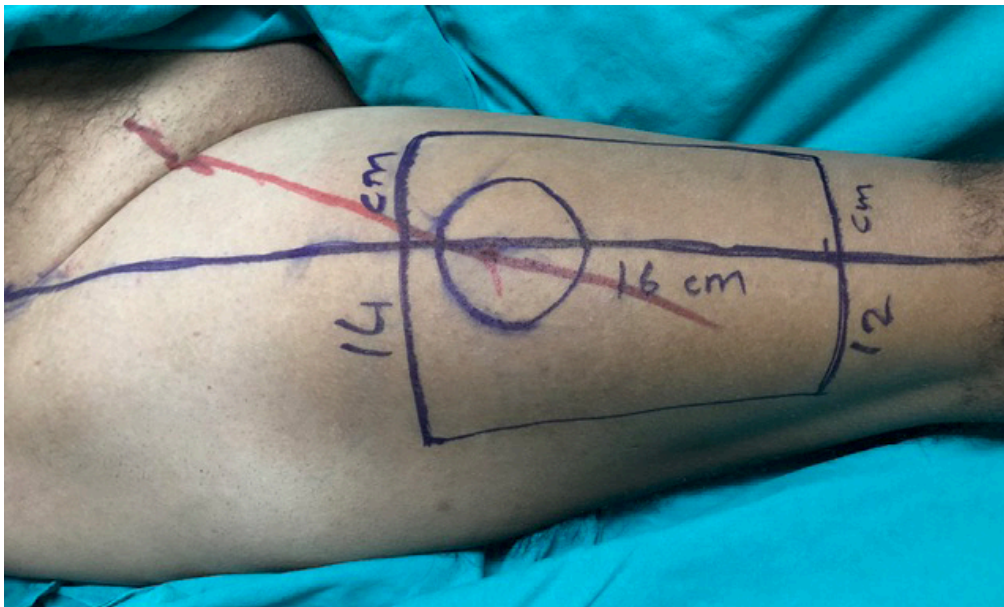
However, due to the limited number of cases who passed the third stage and were followed up adequately, only the first two stages are defined in this study. Each stage, of all cases, was carried out in collaboration of a plastic surgeon and urologist, who are experienced in FtM GAS.

2.4.1 Stage one

Just before the surgery, ALTh perforators are determined with an 8 MHz portable hand-held doppler ultrasonography (USG) again, and marked on the skin (Fig. 1). The flap is centered along a line, representing the intermuscular septum, between the rectus femoris and vastus lateralis muscle joining proximally the anterior superior iliac crest and distally the upper lateral border of the patella. The ALTh is formed, in

TABLE 1. Postoperative follow-up satisfaction inquiry for female to male gender affirming surgery.

Please answer the following questions according to your satisfaction level?					
(Definitely no: 0 point (1), No: 2 point (2), No idea: 4 point (3), Yes: 6 point (4), Definitely yes: 8 point (5))					
1	Are you satisfied with your outlook in general?	1	2	3	4 5
2	Are you satisfied with your female to male gender affirming surgery?	1	2	3	4 5
3	Are you satisfied with the aesthetic results of the surgery?	1	2	3	4 5
4	Are you satisfied with the functional results of the surgery?	1	2	3	4 5
5	Are you currently more satisfied with your life?	1	2	3	4 5
6	Did your acceptance as a man increased by the society?	1	2	3	4 5
7	Did your life become socially easier?	1	2	3	4 5
8	Do you feel yourself closer to the gender you desire?	1	2	3	4 5
9	Would you recommend male to female gender affirming surgery to other transmen?	1	2	3	4 5
10	Did you regret the surgery?	5	4	3	2 1
Total Score:					
Percentage:					

**FIGURE 1. Determination of Antero Lateral Thigh flap perforators with doppler ultrasonography and marking on the skin.**

a trapezoidal rectangular shape varying between $14 \times 16 \times 12$ cm and $12 \times 14 \times 10$ cm of dimensions, and is harvested in standard supine position. Mainly, the donor limb is chosen according to the person's preference, if not the non-dominant limb is used.

In order to define the lateral femoral cutaneous nerve, the dissection of the flap starts proximally and is lifted through the suprafascial plane, medial to lateral, over the rectus femoris. The rectus femoris fascia is then cut, and dissection continues to the subfascial plane launching the gap between the rectus femoris and vastus lateralis. After perforating vessels are freely dissected through the fascial and intramuscular course, the remainder of the dissection can be completed suprafascially. Considering the size of the flap, no matter how meticulously it is harvested, thinning is not recommended as it may impair perfusion. After complete isolation of perforator

vessels, the pedicle is pursued proximally. Meanwhile, the dissection of arteria profunda femoris is important to allow the flap to reach the pubic midline. Therefore, pedicular dissection should be up to the depth of the femoral vascular branches. Subsequently, rectus femoris and sartorius muscles are elevated to allow the flap and accompanying vascular structures to pass underneath without causing any compression (Fig. 2A,B).

For an easy and a secure positioning of the neo-phallus, the recipient area should be created at the lower border of the symphysis pubis, under the guidance of the existing genital structures, by a large enough and arc shaped incision which is carried out directly to the suprapubic fascia. Eventually, after the prepared thigh flap is shaped as "tube-in-tube" or folded on itself and passed smoothly underneath the muscles, it is fixed to the recipient area (Fig. 3).

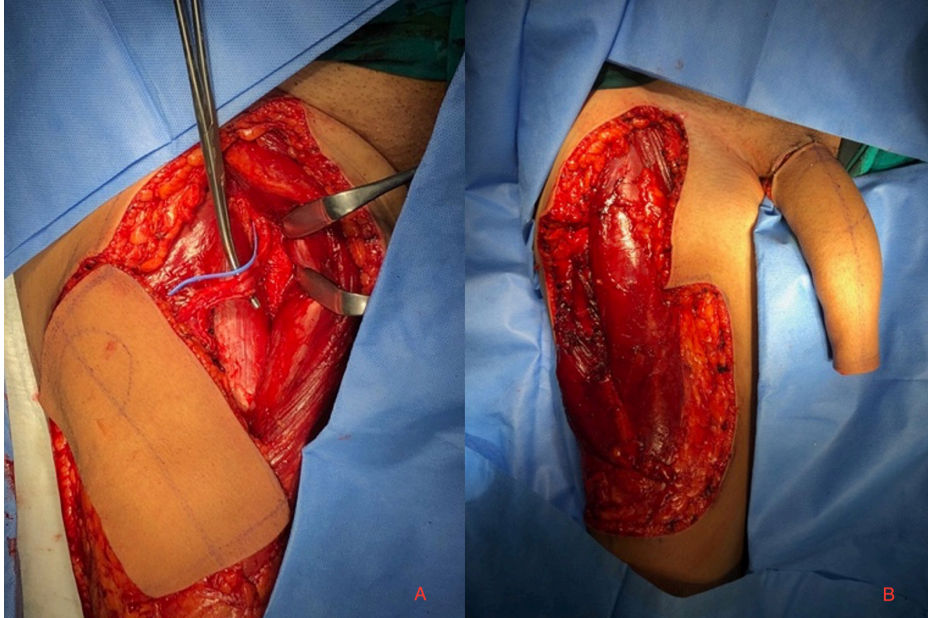


FIGURE 2. Elevating the rectus femoris and sartorius muscles. (A) Flap and accompanying vascular structures. (B) Rectus femoris and sartorius muscles.

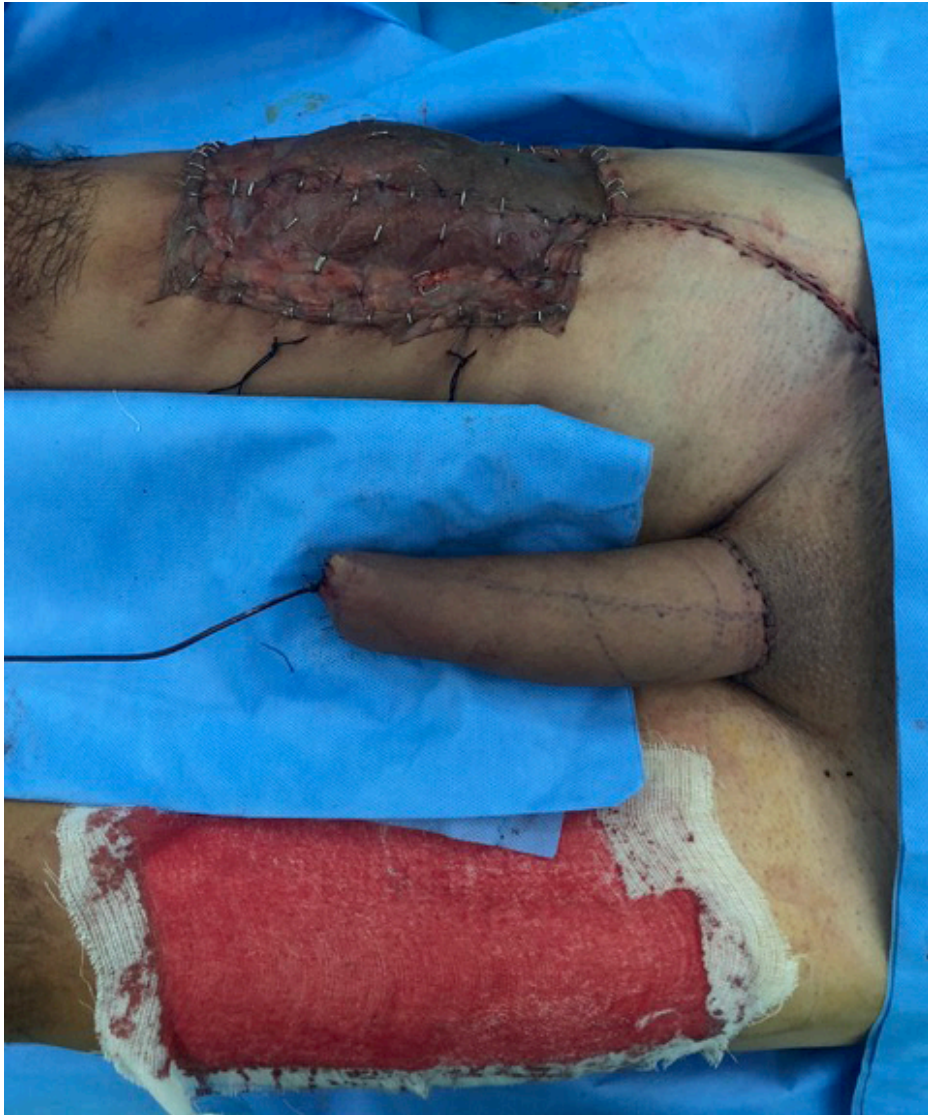

FIGURE 3. Fixation the thigh flap in the shape of “tube in tube” to the recipient area.

2.4.2 Stage two

The most important part of this stage includes the urethral reconstruction.

Formation of the neo-urethra in ALTF phalloplasty is planned according to the “Pinch test” [4]. If subcutaneous fatty tissue thickness of the thigh is <1.5 cm, the urethra is marked on the donor site and prepared directly during flap harvesting to form a “tube-in-tube” shaped neo-phallus. However, if it is >1.5 cm, additional flap or graft substitution from other donor sites is required for urethral trans-positioning.

The surgery mainly begins with the vaginal closure, in which it is carefully dissected from surrounding tissues, *i.e.*, the rectum, proximal urethra and bladder neck, and excised as proximal as possible.

Urethral reconstruction, in our cases, is carried out in two ways. In cases not requesting the meatus to the tip of the neo-phallus, a urethral elongation was performed (Fig. 4). Therefore, the peri-clitorideal mucosal area is prepared to obtain an approx. 4–5 cm vascular bed, which is afterwards tubularized and proximally anastomosed to the urethral meatus and distally fixed near to the radix of the neo-phallus. In all our cases, who requested their urethra to the tip and refused an additional visible donor site had a “Pinch test” >1.5 cm, therefore an inguinal full thickness skin graft was taken to create the neo-urethra. After the graft is tubularized on an 18ch Foley catheter (Fig. 5) it is placed through the created neo-meatal opening into the neo-phallus and anastomosed with the elongated neo-urethra.

The clitoris, on the other hand, is released after desepithelization to allow trans-positioning of its volar and dorsal attachments to the recipient site. After the clitoral nerve is located and isolated, on the adjacent side of the flap donor, the clitoral hood is fixed onto the neo-urethral anastomosis below the level of the symphysis pubis (Fig. 6). Hereby, besides providing an additional vascular supply to the neo-urethral anastomosis, stimulation from the radix of the neo-phallus can maintain erogenous sensation even in cases with weak or absent cutaneous nerve healing.

2.5 Statistics

Descriptive statistical analysis was performed with the IBM Statistical Package for Social Sciences 23.0 (SPSS, Chicago, IL, USA) package program. Considering the sample size, the Shapiro-Wilk test was used to decide on the normality assessment of the data and it was found that it was not normally distributed. Thus, continuous data were expressed as median and interquartile range, and categorical variables were expressed as numbers (n) and percentage (%).

3. Results

Demographic data including medical history, case characteristics and length of hospitalization are shown in Table 2.

The median age, follow-up period and preoperative body mass index (BMI) of our 26 cases included in the study, was 30 (28–34) years, 31.5 (22.2–45.2) months and 24.4 (22.3–26.1) kg/m², respectively. Systemic diseases and personal habits, such as Hypertension (n = 1), Asthma (n = 2), Diabetes

TABLE 2. Demographic data and postoperative follow-up data.

Number of cases (n)	26
Age (year)*	30 (28–34)
Body Mass Index (kg/m ²)*	24.4 (22.3–26.1)
Systemic disease (n/%)	4 (15.4%)
Smoking (n/%)	15 (57.80%)
Hospital stay (day)*	
Stage 1	6 (5–6)
Stage 2	6 (5.25–6)
Follow-up (month)*	31.5 (22.2–45.2)
Tactile Sensation (n/%)	
Radix	17 (65.4%)
Corpus	7 (26.9%)
Tip	2 (7.7%)

*Given as median (Interquartile range).

Mellitus (n = 1) and smoking (n = 15), were determined according to their medical records.

The mean penile length and diameter measured at the late first postoperative follow-up examination of stage two, were 15.07 ± 0.98 cm and 3.9 ± 0.34 cm respectively. Tactile sensation was also evaluated and recorded at the radix, corpus and tip of the neo-phallus showing response in 17 (65.4%), 7 (26.9%) and 2 (7.7%) of the cases, respectively.

In 13 (50%) cases, the urethra was trans-positioned to the tip of the neo-phallus by using a full-thickness inguinal graft, whereas in the other 13 (50%) cases a simple neo-urethral elongation was performed. No urethral complication was observed in cases with neo-urethral elongation. However, meatal stenosis together with urethral fistula in three (11.5%), and concurrent meatal and urethral stenosis in four (15.4%) cases, who had undergone neo-urethral trans-positioning to the tip, was observed. In 14 (53.8%) of all cases no complication was reported at all. However, in 12 (46.1%) cases, although no intraoperative complication occurred, postoperative complications and their managements according to Clavien-Dindo Classification are summarized in Table 3.

According to our follow-up inquiry, that interrogates postoperative mental, social and physical health in general, the average of the inquiry scores of all patients was calculated as 61.7 points, which corresponds to satisfaction rate of 77.14% (38–94).

4. Discussion

An aesthetic neo-phallus, penetration with tactile and erogenous sensation, minimal flap and donor site complications and smooth micturition are the most important goals in FtM GAS [4, 9]. In this regard, without the need for a potential microsurgery and vascular anastomosis, the pedicled ALTF provides remarkable outcomes with short ischemia time and minimal flap rejection rates [5, 11–13]. Besides these surgical advantages, the pedicled ALTF provides a donor site that can be easily concealed by dressing, which is particularly noted and

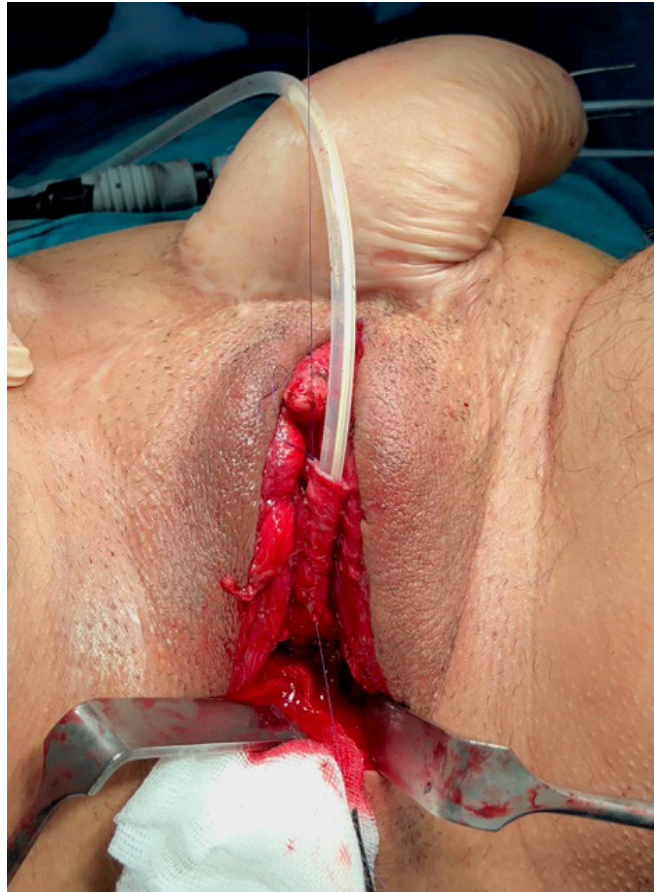

FIGURE 4. Urethral elongation.

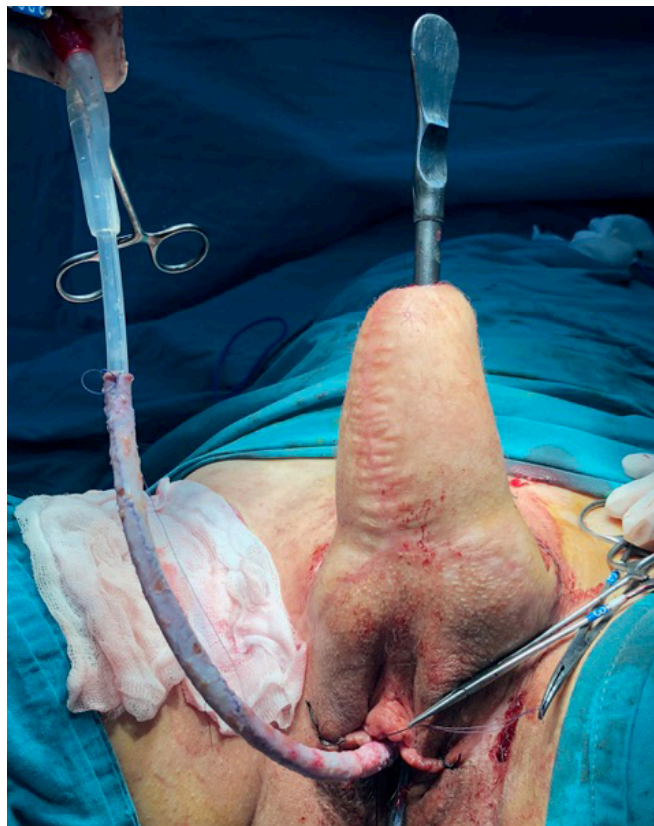

FIGURE 5. Tubularization of the graft on the 18ch Foley catheter.

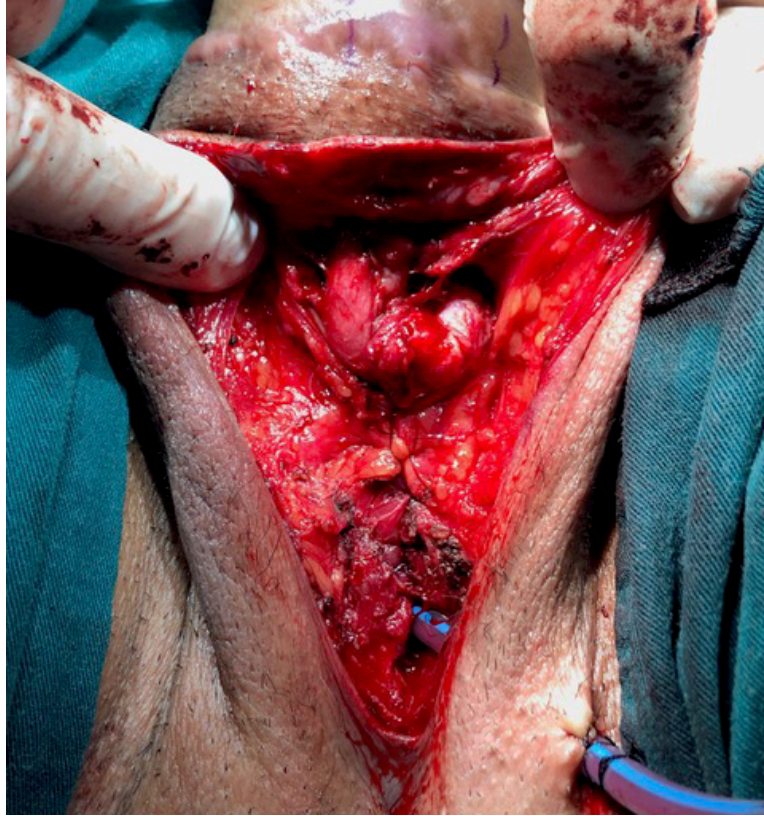

FIGURE 6. Fixation of the clitoral hood onto the neourethral anastomosis.

TABLE 3. Postoperative complications and managements according to clavien-dindo classification.

Complication grade	Management of complications	Rate-n (%)
Clavien 1	-	-
Clavien 2		
Flap Hematoma	Incisional drainage, antibiotics	1 (3.8)
Clavien 3a		
Wound Infection	Debridement, antibiotics	1 (3.8)
Clavien 3b		
Meatal Stenosis	Meatal trans-positioning, Meatal dilatation, Buccal mucosa grafting	6 (23.1)
Urethral Stenosis	Internal urethrotomy, Buccal mucosa grafting, Urethral dilation	4 (15.4)
Urethral Fistula	Primary fistula repair	3 (11.5)
Partial Flap Necrosis	Distal flap excision	1 (3.8)
Penile Ventral Skin Necrosis	Wound grafting	1 (3.8)
Penile Incisional Scar	Local scar revision	4 (15.4)
Clavien 4a	-	-
Clavien 4b	-	-
Clavien 5	-	-

expressed by our cases [11, 12]. In line with previous published data; we have used pedicled ALTf phalloplasty technique, which we presumed to be the first case series of a single center reported from Turkey.

Identification of ALTf perforators is one of the most important steps to avoid flap loss [13]. In all our cases, vascular structures were preoperatively revealed using a hand-held doppler USG and marked on the skin to determine flap

height and width. In certain cases, as defined by Sinove *et al.* [14], Computed Tomography (CT) angiography as well can be used for preoperative evaluation of flap perforators and subcutaneous adipose tissue thickness to determine a feasible flap size.

In cases with a “Pinch test” <1.5 cm, single-stage FtM GAS with ALTf phalloplasty including neo-urethral reconstruction can be possible to prepare, by forming the flap in a “tube-

in-tube” shape. Considering the width required to form the neo-phallus, flaps with a preoperatively higher thickness will result with vascular insufficiency and inappropriate size for intercourse [4]. Due to their high “Pinch test” results and to avoid additional complications, complete formation of the neo-phallus in our cases was carried out in three stages, as suggested by most previously conducted studies [7, 15].

Depending on the limited availability of physicians and centers dealing with GAS in our country, clinical applications are mostly from very distant regions. Consequently, due to complications that develop, the need for recurrent interventions in these cases can cause adjunct financial issues (transportation, accommodation, *etc.*) and further time delay of transitional completion, in addition to psychological and emotional burden. Therefore, if possible, a single-stage urethral reconstruction with the lowest complication rate that can be achieved should be determined by a joint decision of both patient and surgeon. Although, the ability to void upright has been referred as one of the ideal goals of a phalloplasty, neo-urethral transpositioning to the tip was less frequently demanded by our cases, unlike the current literature. This difference mainly arose due to the change of preference, after being informed that most of the complications were related to the neo-urethra, in cases where seated urination was common according to their religious beliefs. Furthermore, fear of cultural prejudices, which could lead to reduced postoperative social acceptance and mental deterioration, led our cases to choose/prefer a donor site that could be concealed while dressing.

4.1 Patient satisfaction

The vast majority of current information, on the results obtained in FtM GAS regarding case satisfaction, is considered to be of low-quality of evidence. Due to the lack of controlled/prospective studies, low response rates in long-term studies, and standard nomograms consisting of components such as cosmetic, sexual, functional, social and psychological status, available outcomes of postoperative case satisfaction during follow-up is inadequate [10, 16].

In a previously published study in this regard, it was reported that, 72% of cases were accepted by their family, friends and other people, and 86% were mainly satisfied with their new lives [17]. In the study of De Cuypere *et al.* [18], in which the physical, emotional and social levels of satisfaction were questioned and determined as 81.5%, 94.4% and 90.7%, respectively; common sexual satisfaction levels, after a six-year follow-up period, was reported as 76% for transwomen and 89% for transmen.

Considering our results, with a mean follow-up period of 44.1 ± 15.7 months, satisfaction levels of transmen with 77.14%, have shown correlation with the literature (Table 2).

4.2 Complications

Most detected postoperative complications in cases undergoing FtM GAS are related to the neo-urethra, such as strictures and fistulas, which can be mostly managed by open and/or endoscopic techniques [10, 11, 16].

Use of a second donor site for urethral reconstruction has been reported in cases not eligible for a “tube-in-tube” shaped

phalloplasty [5, 7, 19–22]. None of our cases preferred the use of a second donor site for various reasons: radial forearm flap (RFF) because of donor site visibility, superficial circumflex iliac artery flap (SCIAF) because of relatively high loss rates, and buccal mucosal graft because of the necessity for multiple stages as well as the potential use for revisions rather than primary cases [19, 20, 22].

Reviewing the literature, less information is available about the results of skin grafts used for neo-urethral reconstruction in transmen. Studies using free skin grafts in ALTf phalloplasty were reported by Felici *et al.* [7], with no urethral complications; and Darpa *et al.* [20], showing no fistula whereas stenosis was observed in seven out of eight cases. Although the location and length of the stenotic segments were not specified, D’Arpa *et al.* [20] noted that all cases were able to void upright, after adequate treatment [7, 14]. With a mean follow-up of 44.1 ± 15.7 months, neo-urethral complications were observed in seven (27%) of our cases of which four were able to void upright after multiple endoscopic and/or open surgical interventions. Despite that, due to some personal matters described before, three cases demanded to re-substitute their neo-urethra back to the previous proximal elongated segment, to confront less complications.

The most important and non-urethral complication in FtM GAS is flap loss. In a systematic review comparing multiple techniques, published in 2016, it has been shown that pedicled ALTf phalloplasty has lower flap loss rates compared to all other techniques, with no total and only one partial flap loss [10]. Similarly, no flap loss was experienced in our cases at the first two stages. However, in one case (3.84%) whose first two stages were completed, a 4–5 cm distal segmental flap necrosis, at postoperative day four, after buccal mucosa graft substitution for distal neo-urethral stenosis occurred.

Eventually, some main limitations of our study have to be addressed which were:

(i) the retrospective nature; (ii) the small sample size; (iii) urethral complications that could not be compared between elongation and trans-positioning cases; (iv) incomplete results/data of cases who passed the third stage and, as in all previously conducted studies, (v) the lack of a validated standard satisfaction assessment.

5. Conclusions

Although relevant studies are limited, in addition to low complication rates and high satisfactory outcomes, by leading to a concealable donor site, the pedicled ALTf can be used as a preferred phalloplasty technique, especially in transmen with religious or cultural sensibility.

AVAILABILITY OF DATA AND MATERIALS

Not applicable.

AUTHOR CONTRIBUTIONS

EA and HT—designed the research study. EA and MGA—performed the research. EA, MGA and HT—analyzed the

data; wrote the manuscript. All authors read and approved the final manuscript.

ETHICS APPROVAL AND CONSENT TO PARTICIPATE

Complied with the Declaration of Helsinki, and an institutional ethics committee approval was obtained (TUTF-BAEK 2020/03). Written informed consent was given by all individuals included to this study.

ACKNOWLEDGMENT

The authors thank Jezreel Isachar Pérez Torres for his contribution in the Spanish translation.

FUNDING

This research received no external funding.

CONFLICT OF INTEREST

The authors declare no conflict of interest.

REFERENCES

- [1] Davies RD, Davies ME. The (slow) depathologizing of gender incongruence. *The Journal of Nervous and Mental Disease*. 2020; 208: 152–154.
- [2] Selvaggi G, Dhejne C, Landen M, Elander A. The 2011 WPATH standards of care and penile reconstruction in female-to-male transsexual individuals. *Advances in Urology*. 2012; 2012: 581712.
- [3] Coleman E, Bockting W, Botzer M, Cohen-Kettenis P, DeCuypere G, Feldman J, *et al.* Standards of care for the health of transsexual, transgender, and gender-nonconforming people, version 7. *International Journal of Transgenderism*. 2012; 13: 165–232.
- [4] Xu KY, Watt AJ. The pedicled anterolateral thigh phalloplasty. *Clinics in Plastic Surgery*. 2018; 45: 399–406.
- [5] Lee GK, Lim AF, Bird ET. A novel single-flap technique for total penile reconstruction: the pedicled anterolateral thigh flap. *Plastic and Reconstructive Surgery*. 2009; 124: 163–166.
- [6] Monstrey S, Ceulemans P, Hoebeke P. Sex reassignment surgery in the female-to-male transsexual. *Seminars in Plastic Surgery*. 2011; 25: 229–244.
- [7] Felici N, Felici A. A new phalloplasty technique: the free anterolateral thigh flap phalloplasty. *Journal of Plastic, Reconstructive & Aesthetic Surgery*. 2006; 59: 153–157.
- [8] Jun MS, Pušica S, Kojovic V, Bizic M, Stojanovic B, Krstic Z, *et al.* Total phalloplasty with latissimus dorsi musculocutaneous flap in female-to-male transgender surgery. *Urology*. 2018; 120: 269–270.
- [9] Monstrey S, Hoebeke P, Selvaggi G, Ceulemans P, Van Landuyt K, Blondeel P, *et al.* Penile reconstruction: is the radial forearm flap really the standard technique? *Plastic and Reconstructive Surgery*. 2009; 124: 510–518.
- [10] Morrison SD, Shakir A, Vyas KS, Kirby J, Crane CN, Lee GK. Phalloplasty: a review of techniques and outcomes. *Plastic & Reconstructive Surgery*. 2016; 138: 594–615.
- [11] Ascha M, Massie JP, Morrison SD, Crane CN, Chen ML. Outcomes of single stage phalloplasty by pedicled anterolateral thigh flap versus radial forearm free flap in gender confirming surgery. *Journal of Urology*. 2018; 199: 206–214.
- [12] Morrison SD, Son J, Song J, Berger A, Kirby J, Ahdoot M, *et al.* Modification of the tube-in-tube pedicled anterolateral thigh flap for total phalloplasty: the mushroom flap. *Annals of Plastic Surgery*. 2014; 72: S22–S26.
- [13] Esmonde N, Bluebond-Langner R, Berli JU. Phalloplasty flap-related complication. *Clinics in Plastic Surgery*. 2018; 45: 415–424.
- [14] Sinove Y, Kyriopoulos E, Ceulemans P, Houtmeyers P, Hoebeke P, Monstrey S. Preoperative planning of a pedicled anterolateral thigh (ALT) flap for penile reconstruction with the multidetector CT scan. *Handchirurgie, Mikrochirurgie, plastische Chirurgie*. 2013; 45: 217–222.
- [15] Rubino C, Figus A, Dessy LA, Alei G, Mazzocchi M, Trignano E, *et al.* Innervated island pedicled anterolateral thigh flap for neophallic reconstruction in female-to-male transsexuals. *Journal of Plastic, Reconstructive & Aesthetic Surgery*. 2009; 62: e45–e49.
- [16] Frey JD, Poudrier G, Chiodo MV, Hazen A. An update on genital reconstruction options for the female-to-male transgender patient: a review of the literature. *Plastic & Reconstructive Surgery*. 2017; 139: 728–737.
- [17] Berg JEA, Gustafsson M. Long term follow up after sex reassignment surgery. *Scandinavian Journal of Plastic and Reconstructive Surgery and Hand Surgery*. 1997; 31: 39–45.
- [18] De Cuypere G, TSjoen G, Beerten R, Selvaggi G, De Sutter P, Hoebeke P, *et al.* Sexual and physical health after sex reassignment surgery. *Archives of Sexual Behavior*. 2005; 34: 679–690.
- [19] van der Sluis WB, Smit JM, Pigot GLS, Buncamper ME, Winters HAH, Mullender MG, *et al.* Double flap phalloplasty in transgender men: surgical technique and outcome of pedicled anterolateral thigh flap phalloplasty combined with radial forearm free flap urethral reconstruction. *Microsurgery*. 2017; 37: 917–923.
- [20] D’Arpa S, Claes K, Lumen N, Oieni S, Hoebeke P, Monstrey S. Urethral reconstruction in anterolateral thigh flap phalloplasty: a 93-case experience. *Plastic & Reconstructive Surgery*. 2019; 143: 382e–392e.
- [21] Zhang Y, Liu C, Qu C, Lu L, Liu A, Zhu L, *et al.* Is vaginal mucosal graft the excellent substitute material for urethral reconstruction in female-to-male transsexuals? *World Journal of Urology*. 2015; 33: 2115–2123.
- [22] Wilson SC, Stranix JT, Khurana K, Morrison SD, Levine JP, Zhao LC. Fasciocutaneous flap reinforcement of ventral onlay buccal mucosa grafts enables neophallus revision urethroplasty. *Therapeutic Advances in Urology*. 2016; 8: 331–337.

How to cite this article: Ersan Arda, Mehmet Gürkan Arıkan, Hüsamettin Top. The pedicled Antero lateral thigh flap for gender affirming surgery: what is different? First case series outcomes of a single center from Turkey. *Revista Internacional de Andrología*. 2024. doi: 10.22514/j.androl.2024.008.